

# Neurosurgical Quarterly Topic Review

*“It’s all about the patient”*

## Meningioma Case 1

### Chief complaint

The patient is a 45 year old male who presented with new onset seizures.

### History of present illness

The patient was well until he experienced a tonic-clonic convulsion while working as a plumber in a crawlspace. The seizure lasted approximately one minute. His coworkers called 911 and he was taken to the emergency room. There, he was found to be intact. He stated that he had bitten the left side of his tongue and bruised his face but was not incontinent. There was no history of weakness, numbness, tingling, headache, nausea, vomiting or visual disturbance. A CT scan showed a 3.5 cm mass along the right medial sphenoid wing. A loading dose of Dilantin was given and the patient was seen in the office the next day.

### Examination

On general examination there were abrasions over the right forehead and nose. There was a laceration along the left buccal aspect of the tongue. General physical and neurologic examination were unremarkable.

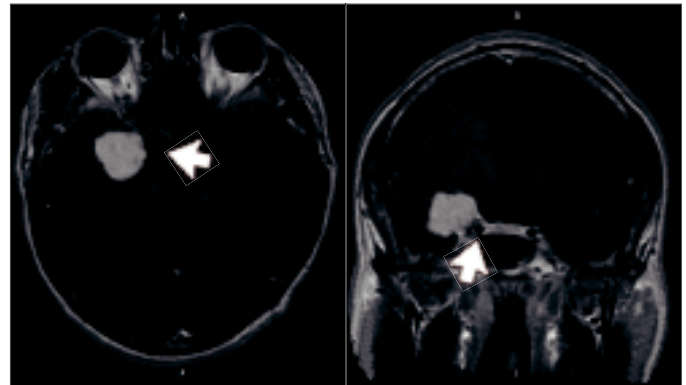
**Radiographic studies:** The patient underwent MRI of the brain (Figs 1a, b) and cerebral angiography with embolization of the tumor. Figures 2a and 2b demonstrate pre- and post-embolization angiograms of the medial sphenoid wing meningioma.

### Treatment

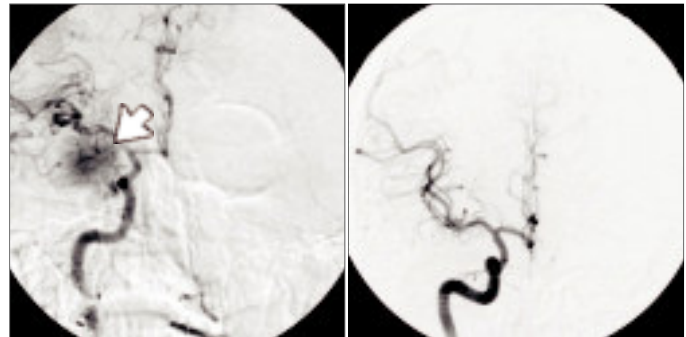
One day post-embolization the patient was taken to the operating room for craniotomy and excision of tumor. The patient was administered general anesthesia and a foley catheter, central venous line and radial arterial line were placed. The head was placed in three point skull fixation and positioned for a pterional craniotomy. Ancef one gram, Decadron 20 mg and Lasix 10mg were administered. A lumbar spinal drain was inserted to facilitate drainage of cerebrospinal fluid, allowing for additional intraoperative brain relaxation. The operating microscope was used because of the medial location of the tumor along the sphenoid wing and its intimate relationship with the carotid artery, cranial nerves III through VI and the cavernous sinus. EEG monitoring remained normal throughout the operation. A gross total resection of the tumor was achieved. (Figs 3a, b)

### Postoperative course

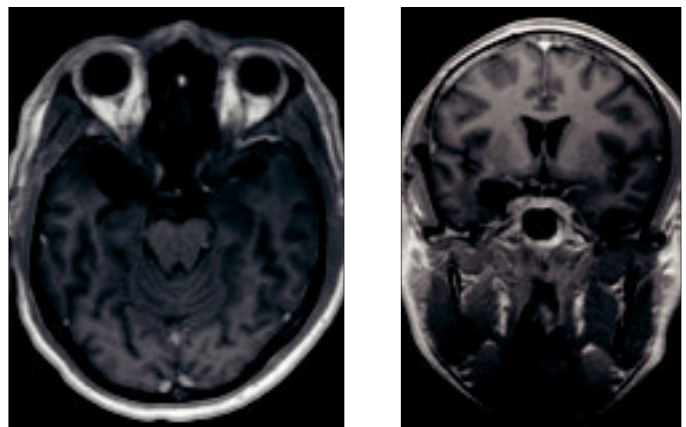
The patient woke with a complete IIIrd nerve palsy OD and numbness and tingling in the V1, V2 and V3 distributions of the right trigeminal nerve. One month postoperatively he developed a deep venous thrombosis for which he was placed on Coumadin. By nine months later the IIIrd nerve palsy had resolved. The patient felt slight tingling in the right forehead, right side of the nose and a small portion of the upper lip but there was no objective decreased sensation to light touch or pinprick. He has returned to work as a plumber.



*Figs 1a, b: Axial and coronal images of a 3.5 cm homogeneously enhancing right medial sphenoid wing meningioma. Note intimate relationship of tumor with cavernous carotid artery (arrow).*



*Figs 2a, b: Pre- and post-embolization anteroposterior angiograms. Pre-embolization study shows significant blush (arrow) while post-embolization study shows significantly decreased blood flow to the tumor.*



*Figs 3a, b: Postoperative MRI in the axial and coronal plane after the administration of gadolinium shows no evidence of recurrent tumor and small amount of medial temporal encephalomalacia.*

# Meningioma

## Case 2

### Chief complaint

The patient is a 59 year old male who presented with a chief complaint of loss of smell of two years' duration.

### History of present illness

The patient was well until two years ago when he noticed the sudden onset of loss of smell. Sense of smell returned and fluctuated until three months prior to being seen. At that time, he noticed complete absence of smell which had not improved. There was no history of weakness, numbness, tingling, headache, nausea, vomiting, fever, chills, night sweats, weight loss or visual disturbance. It was stated by his wife that he had not been as passionate about certain things (politics) or as verbal as was typical for him. The patient's wife characterized him as having been apathetic for over a year.

### Examination

The patient was anosmic but otherwise neurologically intact.

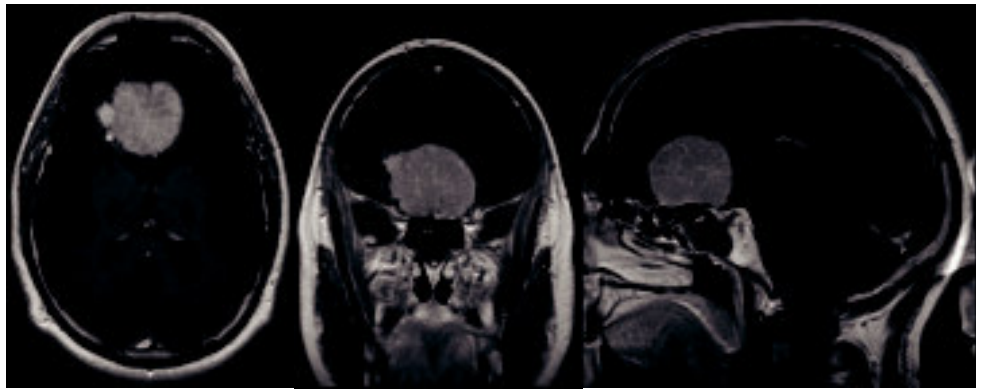
**Radiographic studies:** MRI of the brain (Figs 4a, b, c) shows a 5 cm mass which is bifrontal in location arising from the planum sphenoidale with significant surrounding bifrontal edema on the T2 weighted image (not shown).

### Treatment

The patient was taken to the operating room for bifrontal craniotomy and excision of tumor. Ancef 1 gram, Decadron 20 mg, Lasix 20 mg, Mannitol 12.5 gm and Phenobarbital 260 mg were given. A spinal drain was placed to facilitate brain relaxation. He was then placed in three point skull fixation in the brow-up position. A bicoronal incision (Figs 5a, b) was made, allowing for a bifrontal craniotomy and excision of tumor using the microscope and ultrasonic aspirator. Post-operatively, the patient was neurologically unchanged. Post-operative hyponatremia lasting one month was treated with fluid restriction and salt replacement. Eight months after surgery, MRI showed no evidence of recurrent tumor. (Figs 6a, b, c)

### Discussion

Meningiomas are typically benign neoplastic lesions that constitute 20% of primary intracranial brain tumors and may occur anywhere along the neuraxis. They are usually noninvasive, arise from the meninges and are slow growing. They usually occur in the middle aged or elderly patient. Large intracranial tumors associated with edema may present with symptoms related to increased intracranial pressure (headache, nausea, vomiting), seizure or neurologic deficit, secondary brain or cranial nerve compression.

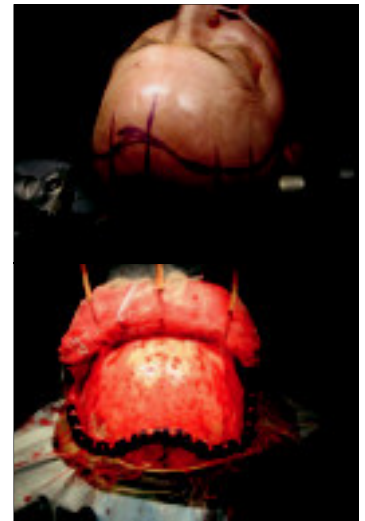


*Figs 4a, b, c: T1 weighted, gadolinium enhanced MR images in the axial, coronal, and sagittal planes demonstrates a 5 cm homogeneously enhancing mass in the subfrontal region consistent with a planum sphenoidale meningioma.*

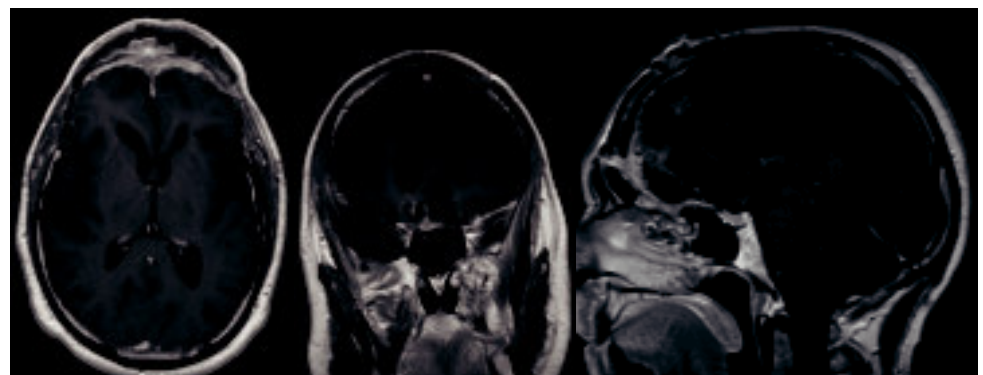
Meningiomas are surgical lesions. However, gross total resection may not be performed if the patient is at risk for significant neurologic compromise.

Surgical difficulty is often determined by the degree of local adherence and invasiveness of the tumor to contiguous structures such as cranial nerves and arteries. Subtotal resection may result. Residual tumor that is unresectable may be treated with Gamma Knife radiosurgery. These tumors were removed by using a debulking technique with an ultrasonic aspirator.

This method of tumor removal allows the tumor capsule to collapse upon itself, minimizing brain retraction. Even with gross total excision, tumor recurrence may occur. Patients should be followed with MR imaging annually. In these cases, both patients returned to their normal daily activity.



*Figs 5a, b: The bicoronal incision allows access to both frontal lobes as well the anterior fossa skull base.*



*Figs 6a, b, c: T1 weighted, gadolinium enhanced MR images in the axial, coronal and sagittal planes shows no evidence of recurrent tumor.*